

## Letter to the Editor

### Immunotherapy-induced interstitial lung disease: Cases report

DOI: 10.4103/sajc.sajc\_23\_19

Dear Editor,

Immune checkpoint inhibitors (ICIs) have revolutionized the treatment since their introduction. ICIs are emerging as second-line therapy in advanced nonsmall cell lung cancer (NSCLC). Although therapy with ICIs has shown significant regression in multiple cases, it has also been associated with certain immune-related adverse events such as pruritus and endocrinopathies. The incidence of pneumonitis with immune checkpoint inhibitors is 4% and carries high morbidity.<sup>[1]</sup>

Helber *et al.*<sup>[2]</sup> reviewed five cases of ICI-induced pneumonitis. One patient died of Grade 5 pneumonitis and the other four had Grade 3 and survived. Radiological pattern mostly observed was ground glass. None underwent biopsy, and all patients were empirically treated with intravenous steroids and antibiotics.

Leroy *et al.*<sup>[3]</sup> described three cases of ICI-induced pneumonitis and organizing pneumonia were diagnosed in two of the three cases. Based on the radiological patterns, cases 1 and 2 were classified as organizing pneumonia, and case 3 as nonspecific interstitial pneumonia.

Akella *et al.*<sup>[4]</sup> described two cases of such immune-related adverse effects associated with immune check point inhibitors with recovery in one of the patients.

In a retrospective study by Delaunay *et al.*<sup>[5]</sup> conducted in participants who mainly received programmed death-ligand-1 inhibitors showed that interstitial lung disease (ILD) is more common in males, smokers, with a median age of

59 years. They observed that the median time from the start of immunotherapy to ILD was roughly 15 days to 24 months, occurring earlier in lung cancer than melanoma. Predominant lesions were found to be ground-glass opacities more than consolidations, and no clear risk factors were identified.

Factors such as smoking history, COPD, and underlying fibrosis contribute to a higher incidence of pneumonitis in NSCLC patients.<sup>[6-9]</sup> As underlying lung parenchyma is frail, any stress from outside can be a contributing factor. Existing tumor burden in the lung can also be a contributing factor limiting the tolerance of lung tissue to exogenous stress.<sup>[6]</sup>

These predisposing factors lead to increase in the overall risk of NSCLC patients to develop Grade 3 or higher pneumonitis. ILD is a rare but adverse and fatal event associated with immunotherapy.

A 61-year-old male recently reformed smoker was diagnosed with adenocarcinoma lung in October 2017. Positron-emission tomography-computed tomography (PET CT) revealed pleural nodes with multiple bilateral cervical, bilateral axillary, mediastinal, right internal mammary, and bilateral pelvic and inguinofemoral lymph nodes. Driver mutations were negative. Magnetic resonance imaging of the brain, on initial assessment, was normal. The patient received six cycles of first-line chemotherapy with pemetrexed and carboplatin from December 2017 to April 2018. On assessment, progression was seen 5 months from the start of chemotherapy in lung lesions with new bilateral pleural deposits. Second-line chemotherapy was initiated with paclitaxel and carboplatin from April 2018 to July 2018 for three cycles. PET-CT revealed progression in lung lesion and mediastinal lymph nodes.

In view of progression post 2 lines of chemotherapy, the patient was started on nivolumab 3 mg/kg every 14 days from

(Continue on page 84...)

*(Letter to the editor continue from page 79...)*

July 2018. After three cycles of nivolumab, the patient presented with a cough, breathing difficulty, and hypoxia. CT done showed [Figure 1b] widespread septal thickening and ground-glass density in the left lung as a new development representing active ILD which was not present before starting immunotherapy [Figure 1a]. Apart from the ground-glass densities and septal thickening, lung volume loss and lung architectural distortion were seen. Bronchoscopy was performed and bronchoalveolar lavage did not grow any pathogens. Transbronchial biopsy (TBB) was suggestive of usual interstitial pneumonia (UIP). Antibiotic therapy with ceftriaxone and clarithromycin was initiated, and oxygen intake with nasal catheter was maintained. Methylprednisolone was started at the dose of 1 g once daily that was subsequently tapered. The patient responded to treatment and was discharged after 1 week

on oral prednisolone and fluconazole. Patient was readmitted after few days with breathlessness and hypoxia. The patient was started on levofloxacin, meropenem, amphotericin B, and methylprednisolone. Oxygen support was given through nasal mask, and patient was started on noninvasive positive pressure ventilation in view of hypoxia and hypercarbia. Patient's condition continued to worsen with progressive hypoxia and drowsiness for which patient was treated with invasive ventilation. Patient expired on the 3rd day of invasive ventilation.

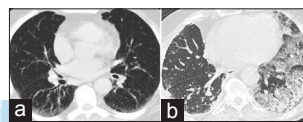
A 40-year-old female, nonsmoker, diagnosed in January 2017 and treated for squamous cell carcinoma of the right lung T3N2M1 (right lower-lobe mass (79 mm × 84 mm × 72 mm) with the right parietal lobe lesion in the brain (17 mm × 18 mm) with perilesional edema and mass

*(Continue on page 91...)*

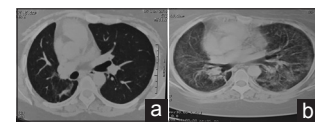
(Letter to the editor continue from page 84...)

effect compressing third and lateral ventricle). Driver mutations were negative.

Patient received image-guided radiation therapy (IGRT) to single brain lesion of dose 36 Gy (Gray) in six fractions from February 4, 2017 to February 13, 2017. After six cycles of chemotherapy with gemcitabine and cisplatin from May 10, 2017 to June 10, 2017, PET-CT showed partial response in the lung. As lung lesion showed response, radiation was given to lung lesion by IGRT technique of dose 39.6 Gy in 22 fractions to primary tumor volume (PTV) and 44 Gy in 22 fractions to gross tumor volume till September 2017. Partial response was seen to radiation. Subsequently, patient progressed in the brain and developed multiple brain lesions for which whole-brain radiation therapy by intensity-modulated radiation therapy technique to the brain was given (dose 31.2 Gy in 12 fractions to PTV whole brain and simultaneous dose of 45 Gy in 12 fractions to gross space occupying lesions (SOLs) from November 22, 2017 to December 7, 2017. After completion of radiation, repeat PET scan showed progression at primary lung lesion. The patient was started on nivolumab 3 mg/kg from January 2018. Post 6 cycles developed oligoprogression in iliac muscle with no change in the right lung primary. Patient received 3 fractions of IGRT (dose 24 Gy) to left iliac deposits from May 3, 2018 to May 5, 2018. After 14 cycles of nivolumab presented with shortness of breath and CT showed [Figure 2b] extensive bilateral areas of ground-glass attenuation as compared to CT of the chest done at last assessment which was done 3 months prior [Figure 2a]. The radiological appearance of honeycombing was seen along with bilateral reticular densities were started on prednisolone at 1 mg/kg but did not respond. Bronchoscopy was done and broncho alveolar lavage (BAL) did not reveal any growth of pathogens. In TBB, no lung tissue was seen, so could not be commented on. Diagnosed with ILD was made on clinical and radiological grounds [Figure 2b]. The patient was started on methylprednisolone (1 g once daily), but the condition did not improve and died.



**Figure 1: (a) Computed tomography of the chest and preimmunotherapy with nivolumab. (b) Computed tomography of the chest post 3 cycles of immunotherapy with nivolumab**



**Figure 2: (a) Computed tomography of the chest before immunotherapy. (b) Computed tomography of the chest after 14 cycles of immunotherapy**

Here, we report two cases of with respiratory symptoms and infiltrates with immunotherapy. Their workup concludes the diagnosis of UIP in one based on TBB and presumed ILD in the second case based on the radiological report. Both cases were treated with steroids but eventually passed. It is difficult to rule out other etiologies like infection, other drug-related pneumonitis or radiation pneumonitis. We did bronchoscopy for both of our patients to rule out other causes, and in the first case, TBB showed UIP and for second patient TBB did not show any lung tissue. For the second patient, the diagnosis of ILD was made on clinical and radiological grounds.

The first patient presented after three cycles only, whereas for the second patient after 15 cycles. Immunotherapy was stopped for both patients. According to a diagnosis and treatment review of checkpoint inhibitor-related pneumonitis by Sarah Chuzi *et al.*,<sup>[10]</sup> case 1 had Grade 3/4 ILD, whereas case 3 had Grade 2 ILD. Both cases had similar cross-sectional CT patterns of diffuse bilateral ground-glass opacities with patchy consolidations which according to the American Thoracic Society and European Respiratory Society are classified as acute interstitial pneumonia with diffuse alveolar damage.<sup>[11]</sup> This diffuse alveolar damage leads to impaired gas exchange which leads to breathlessness/dyspnea causing hypoxia. Although the exact pathogenesis of immunotherapy-induced ILD remains unexplained to this day, henceforth the unsatisfactory management outcomes.

Early diagnosis of ILD in patients undergoing immunotherapy treatment becomes important because of mortality and

(Continue on page 101...)

(Letter to the editor continue from page 91...)

morbidity associated with this disease. Immunotherapy-induced ILD is difficult to diagnose and remains a challenge for the physicians. Other etiologies such as infection, disease progression, chemotherapy, or radiation-induced pneumonitis need to be ruled out.

### Acknowledgment

I am thankful to my coordinators with their support; this work was not possible without their support. (Neha Goel, Mansi Jain, Virender).

### Financial support and sponsorship

Nil.

### Conflicts of interest

There are no conflicts of interest.

**Waseem Abbas<sup>1,2</sup>, Ranga Raju Rao<sup>1,2</sup>,  
Vineet Govinda Gupta<sup>1,2</sup>, Swati Popli<sup>1,2</sup>**

<sup>1</sup>Department of Medical Oncology, Max Institute of Cancer Care,

<sup>2</sup>Max-Super Speciality Hospital Shalimarbagh, New Delhi, India

Correspondence to: Dr. Waseem Abbas,  
E-mail: drabbasdoc@gmail.com

### References

1. Topalian SL, Hodi FS, Brahmer JR, Gettinger SN, Smith DC, McDermott DF, *et al.* Safety, activity, and immune correlates of anti-PD-1 antibody in cancer. *N Engl J Med* 2012;366:2443-54.
2. Helber HA, Hada AL, Pio RB, Moraes PH, Gomes DB. Immunotherapy-induced pneumonitis: Cases report. *Einstein (Sao Paulo)* 2018;16:eRC4030.
3. Leroy V, Templier C, Faivre JB, Scherpereel A, Fournier C, Mortier L, *et al.* Pembrolizumab-induced pneumonitis. *ERJ Open Res* 2017;3. pii: 00081-2016.
4. Akella P, Loganathan S, Jindal V, Akhtar J, Lal A. Anti PD-1 immunotherapy related interstitial lung disease presenting as respiratory failure – A review

- with case series. *Respir Med Case Rep* 2019;26:17-22.
5. Delaunay M, Cadranet J, Lusque A, Meyer N, Gouyant V, Moro-Sibilot D, *et al.* Immune-checkpoint inhibitors associated with interstitial lung disease in cancer patients. *Eur Respir J* 2017;50. pii: 1700050.
6. Nishino M, Giobbie-Hurder A, Hatabu H, Ramaiya NH, Hodi F. Incidence of programmed cell death 1 inhibitor-related pneumonitis in patients with advanced cancer: a systematic review and meta-analysis. *JAMA Oncol* 2016;2:1607-16.
7. Toh CK, Wong EH, Lim WT, Leong SS, Fong KW, Wee J, *et al.* The impact of smoking status on the behavior and survival outcome of patients with advanced non-small cell lung cancer: A retrospective analysis. *Chest* 2004;126:1750-6.
8. Coussens LM, Werb Z. Inflammation and cancer. *Nature* 2002;420:860-7.
9. Bouros D, Hatzakis K, Labrakis H, Zeibecoglou K. Association of malignancy with diseases causing interstitial pulmonary changes. *Chest* 2002;121:1278-89.
10. Chuzi S, Tavora F, Cruz M, Costa R, Chae YK, Carneiro BA, *et al.* Clinical features, diagnostic challenges, and management strategies in checkpoint inhibitor-related pneumonitis. *Cancer Manag Res* 2017;9:207-13.
11. Travis WD, Costabel U, Hansell DM, King TE Jr., Lynch DA, Nicholson AG, *et al.* An official American Thoracic Society / European Respiratory Society statement: Update of the international multidisciplinary classification of the idiopathic interstitial pneumonias. *Am J Respir Crit Care Med* 2013;188:733-48.

This is an open access journal, and articles are distributed under the terms of the Creative Commons Attribution-NonCommercial-ShareAlike 4.0 License, which allows others to remix, tweak, and build upon the work non-commercially, as long as appropriate credit is given and the new creations are licensed under the identical terms.

**How to cite this article:** Abbas W, Rao RR, Gupta VG, Popli S. Immunotherapy-induced interstitial lung disease: Cases report. *South Asian J Cancer* 2019;8:79-101.

© 2019 The South Asian Journal of Cancer | Published by Wolters Kluwer - Medknow