

## Letter to the Editor

### Chronic myelomonocytic leukemia presenting as upper limb gangrene

DOI: 10.4103/sajc.sajc\_16\_18

Dear Editor,

Digital gangrene has several causes including autoimmune, hematological diseases, and infections. Malignancy-associated digital gangrene may coincide, follow, or antedate diagnosis of cancer or herald its recurrence. The prompt recognition of an underlying malignancy in a patient presenting with digital gangrene is necessary for better management.

A 76-year-old widow was admitted with pain and discoloration of medial four fingers of the left upper limb for 10 days. Two days later, she developed blackish discoloration over little finger which progressed to other fingers. She had hypertension for 2 years and was on amlodipine. She denied a history of

weight loss, trauma or any local intervention to the left upper limb, high-risk behavior, drug abuse, and had no history of addictions. She was pale, all peripheral pulsations were palpable equally, and blood pressure was 120/80 mmHg. She had blackish discoloration of the medial four fingers of the left hand and moderate hepatosplenomegaly.

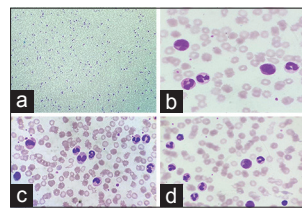
Hemoglobin was 5.8 g/dl (normocytic and normochromic), total leukocyte count 40,000/ml (80% neutrophils, 10% lymphocytes, and 10% monocytes), platelet count 3,20,000/ $\mu$ l, erythrocyte sedimentation rate 82 mm in 1 h, and C-reactive protein was high. Peripheral smear showed normocytic normochromic anemia with marked leukocytosis, monocytosis, and dysplastic myeloid lineage cells (blasts 1%) [Figure 1]. Biochemical parameters showed normal blood sugar levels, renal function tests, liver function tests, and serum electrolytes. Prothrombin time and partial thromboplastin time were normal. Chest X-ray and electrocardiogram were normal.

*(Continue on page 230...)*

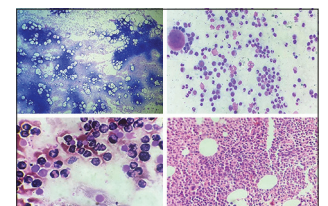
(Letter to the editor continue from page 222...)

HIV, hepatitis B, and hepatitis C serologies were negative. Autoantibody profiles including antinuclear antibody, rheumatoid factor, anti-cyclic citrullinated peptide antibody, c-antineutrophil cytoplasmic antibody, p-antineutrophil cytoplasmic antibody, and antiphospholipid antibodies were all negative. X-ray of skull and serum protein electrophoresis were normal. Urinary Bence-Jones protein was negative. Cryoglobulins were not detected. Skin biopsy did not show any evidence of vasculitis. Ultrasonography showed moderate hepatosplenomegaly. Arterial Doppler of the left upper limb was normal. Bone marrow study was cellular with myeloid hyperplasia and megakaryocytic proliferation along with dysplasia in the myeloid and megakaryocytic lineage [Figure 2]. Cytogenetic studies for detecting platelet-derived growth factor receptor beta gene and breakpoint cluster region-Abelson murine leukemia were negative. A diagnosis of chronic myelomonocytic leukemia with upper limb gangrene was made and was planned for chemotherapy. But unfortunately, she developed hospital-acquired pneumonia with sepsis and succumbed to her illness 2 weeks after admission.

Acral vascular syndromes include digital ischemia, Raynaud's phenomenon, and erythromelalgia. Acral vascular syndromes can be due to various causes such as smoking, autoimmune connective tissue diseases, vasculitis, and local injuries like hammer syndrome.<sup>[1]</sup> When evaluating patients with digital ischemia if history of trauma, drug abuse, local



**Figure 1:** (a) Peripheral smear scanner view showing high white blood cell count (Leishman stain x40); (b-d) significant monocytosis and neutrophilia, with abnormal monocytes and pseudo-Pelger-Huet neutrophil (dysplastic neutrophil) (Leishman stain x1000)



**Figure 2:** (a) Bone marrow aspirate showing highly cellular marrow (Leishman stain x100); (b) dysplastic hypogranular myeloid lineage cells (Leishman stain x400); (c) myeloperoxidase stain highlighting dysplastic myeloid cells (Leishman stain x400); (d) trephine biopsy showing cellular marrow (H and E, x400)

intervention, and infection are excluded and there is no source for emboli, the spectrum narrows down to medical causes for microvascular thrombosis such as hematological and rheological (hyperviscosity syndromes, hypercoagulable states, and vasculitis). Malignancy can also predispose to acral vascular syndrome with a prevalence of paraneoplastic acral vascular syndromes ranging from 2.2% to 8% of cases.<sup>[2]</sup> The mechanisms are not well described, but many hypothetic factors including vasospasm, overproduction of vasoconstrictor factors, intimal proliferation, intraluminal thrombosis, vasculitis,

(Continue on page 239...)

*(Letter to the editor continue from page 230...)*

immune complex, or drug toxicity are proposed. Occurrence of digital ischemia may coincide, follow, or antedate diagnosis of cancer or herald its recurrence.

Adenocarcinomas of lung, breast, and digestive system are the common malignancies associated with digital ischemia.<sup>[3,4]</sup> Hematological malignancies including leukemias, lymphomas, and myeloma are reported to be associated with digital ischemia.<sup>[5-7]</sup> Myeloproliferative disorders including chronic myeloid leukemia and essential thrombocythemia were previously reported to be associated with digital ischemia.<sup>[8,9]</sup> The proposed mechanism in these cases of digital gangrene was thrombocytosis.

Myeloproliferative neoplasm-associated thrombophilia is poorly understood and currently believed to be multifactorial in origin. The mechanisms which contribute include blood hyperviscosity; abnormal clonal cell-endothelium interaction; circulating procoagulant microparticles that express platelet and endothelial markers; impaired endothelial function and repair system; increased state of neutrophil, monocyte, or platelet activation; and acquired activated protein C resistance. Monocytes and neutrophils in myeloproliferative disorders are strongly procoagulant. The mechanisms responsible for the increased procoagulant nature includes; formation of neutrophil-platelet or monocyte-platelet aggregates, upregulation of neutrophil

*(Continue on page 257...)*

(Letter to the editor continue from page 239...)

or monocyte tissue factor expression and abnormal release of inherently procoagulant cellular proteins.<sup>[10]</sup>

Our patient had a negative autoimmune antibody and antiphospholipid antibody profile, negative cryoglobulin normal skin biopsy and arterial Doppler ultrasonography, and no thrombocytosis. The various other hypothetical factors including the strongly procoagulant nature of monocytes and neutrophils may be responsible for the digital ischemia in our patient.

To conclude, when evaluating a patient with digital gangrene, an underlying hematological malignancy should be considered as a cause, and to the best of our knowledge, this is the first report of an association between digital gangrene and chronic myelomonocytic leukemia.

#### Declaration of patient consent

The authors certify that they have obtained all appropriate patient consent forms. In the form the patient(s) has/have given his/her/their consent for his/her/their images and other clinical information to be reported in the journal. The patients understand that their names and initials will not be published and due efforts will be made to conceal their identity, but anonymity cannot be guaranteed.

#### Financial support and sponsorship

Nil.

#### Conflicts of interest

There are no conflicts of interest.

**Lakshmi Priya U, Mansoor C. Abdulla<sup>1</sup>, P. Umashankar**

Departments of Pathology and <sup>1</sup>General Medicine,  
MES Medical College, Malappuram, Kerala, India

**Correspondence to:** Dr. Mansoor C. Abdulla,  
Department of General Medicine, MES Medical College,  
Perinthalmanna, Malappuram - 679 338,  
Kerala, India.

E-mail: drcamans@gmail.com

#### References

1. Gayraud M. Raynaud's phenomenon. *Joint Bone Spine* 2007;74:e1-8.
2. Auboire L, Landy S, Perrot JY, Maiza D, Le Hello C. A negative first-line work-up of Raynaud's phenomenon: And what if it were cancer? *J Mal Vasc* 2010;35:35-7.
3. Le Besnerais M, Miranda S, Cailleux N, Girszyn N, Marie I, Lévesque H, *et al.* Digital ischemia associated with cancer: Results from a cohort study. *Medicine (Baltimore)* 2014;93:e47.
4. Raimondo L. Digital ischemia in patients with solid tumors: A case report and review of the literature. *J Cancer Ther* 2011;2:281-4.
5. Abdulla MC, Nair LK, Narayan R, Das A. Multiple myeloma presenting as extensive limb gangrene. *J Appl Hematol* 2014;5:107.
6. Chang VT, Aviv H, Howard LM, Padberg F. Acute myelogenous leukemia associated with extreme symptomatic thrombocytosis and chromosome 3q translocation: Case report and review of literature. *Am J Hematol* 2003;72:20-6.
7. Woei-A-Jin FJ, Tamsma JT, Khoe LV, den Hartog WC, Gerritsen JJ, Brand A, *et al.* Lymphoma-associated paraneoplastic digital ischemia. *Ann Hematol* 2014;93:355-7.
8. Papadonikolakis A, Chloros GD, Smith BP, Koman LA. Digital ischemia due to essential thrombocythemia: A case report. *J Hand Surg Am* 2007;32:1053-7.
9. Win N, Mitchell DC. Platelet apheresis for digital gangrene due to thrombocytosis in chronic myeloid leukaemia. *Clin Lab Haematol* 2001;23:65-6.
10. Tefferi A. Leukocytosis as a risk factor for thrombosis in myeloproliferative neoplasms-biologically plausible but clinically uncertain. *Am J Hematol* 2010;85:93-4.

This is an open access journal, and articles are distributed under the terms of the Creative Commons Attribution-NonCommercial-ShareAlike 4.0 License, which allows others to remix, tweak, and build upon the work non-commercially, as long as appropriate credit is given and the new creations are licensed under the identical terms.

**How to cite this article:** Priya UL, Abdulla MC, Umashankar P. Chronic myelomonocytic leukemia presenting as upper limb gangrene. *South Asian J Cancer* 2018;7:222-57.

© 2018 The South Asian Journal of Cancer | Published by Wolters Kluwer - Medknow