

Letter to the Editor

A large cystic gastrointestinal stromal tumor within lesser sac: A diagnostic dilemma

DOI: 10.4103/sajc.sajc_10_18

Dear Editor,

Gastrointestinal stromal tumors (GIST) are smooth muscle tumors arising from GI tract. Expression of c-kit, CD 117, etc. separate them from remaining smooth muscle tumors.^[1]

Although commonly solid, they may present as cystic lesions at critical locations and impose diagnostic dilemma in their management. We report such a case to make medical fraternity aware of them.

A 56-year-old male presented with 6 months' history of epigastric pain and fullness. There was no history suggestive of pancreatitis. Serum levels of amylase and lipase were normal. Magnetic resonance imaging (MRI) [Figure 1] showed noncommunicating, thick-walled cystic lesion with hemorrhagic contents in lesser sac 22 cm × 20 cm × 12 cm in size pushing adjacent viscera with pancreatic atrophy with intact pancreatic duct and preserved fat planes with pancreas. Endoscopic ultrasound (EUS) showed extramucosal bulge on the posterior gastric wall with brownish

contents on aspiration. Fluid analysis revealed normal levels of amylase, lipase, carcinoembryonic antigen and carbohydrate antigen (CA) 19.9 and normal cytology. Differential diagnoses were bowel duplication cyst, pancreatic cystic neoplasm, pancreatic pseudocyst, and cystic GIST. Exploratory laparotomy was planned by the multidisciplinary team consisting of oncosurgeon, endoscopist, and radiologist. Exploration showed cystic lesion in lesser sac adherent to surrounding viscera along with amber colored ascites. Ascitic fluid analysis showed normal amylase, lipase, and cytology. Cyst wall biopsy showed high-grade tumor with mitoses suggestive of GIST on frozen section (FS). It was dissected off surrounding viscera and was found to be arising from greater curvature of the stomach. *En bloc* wedge resection of greater curvature along with the mass was performed. Final histology showed high-grade GIST with 5–6 mitoses/50high power field [Figure 2]. Tumor was positive for c-kit [Figure 3], CD 117, CD 34, and SMA with MiB1 index of 35%–40%. The patient was administered adjuvant imatinib. Now, he is disease free at the end of 6-month follow-up.

GISTs originate from the pacemaker cells of muscularis propria, most commonly in the sixth decade. They can be low-to-high grade lesions, depending on the anatomic site, tumor size, and mitotic frequency.^[1,2]

(Continue on page 10...)

(Letter to the editor continue from page 4...)

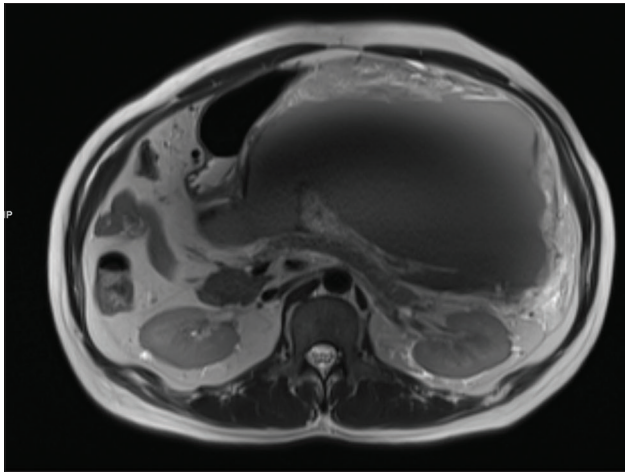


Figure 1: Lesser sac cystic lesion with thick walls and hemorrhagic contents pushing stomach, pancreas with intact fat planes

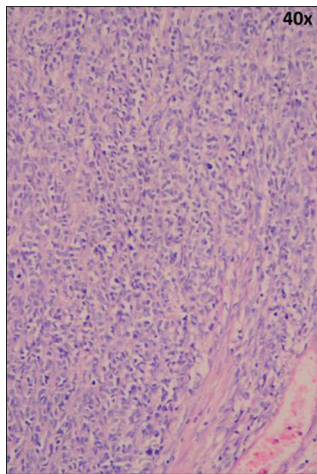


Figure 2: High-grade gastrointestinal stromal tumors with high mitotic rate

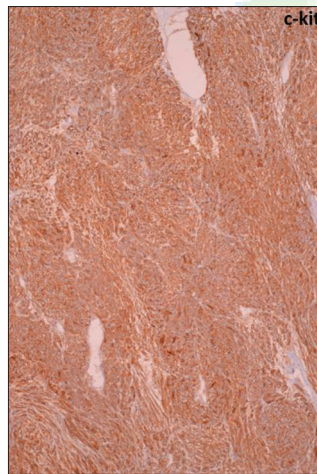


Figure 3: Strong c-kit expression by the tumor

Cystic GIST lesions are rare and invariably impose diagnostic dilemma. Metastases of GIST are often cystic. Furthermore, Neoadjuvant treatment by imatinib also causes central cystic degeneration within tumor. Due to the diagnostic dilemma, in the past, they have been treated as pseudocyst of pancreas,^[3,4] undergone radical resections thinking of aggressive cystic malignant tumors of pancreas.^[5]

Our patient was diagnosed by a family physician as pseudocyst of the pancreas.

It was important to differentiate a neoplasm from the pseudocyst preoperatively as the surgical approach needed for both are drastically different (cystogastrostomy for pseudocyst and excision for a neoplasm). Judicious use of MRI, EUS, FS, and multidisciplinary team discussion helped us to manage the case optimally.

Cystic GISTs are rare and impose diagnostic challenge. The possibility of GIST should be considered when investigating large, cystic lesions in association with GI tract. Judicious use of radiological imaging, multidisciplinary team discussions, intraoperative FS, and optimum patient counseling are imperative while managing such tricky cases to achieve most optimal results.

Declaration of patient consent

The authors certify that they have obtained all appropriate patient consent forms. In the form the patient(s) has/have given his/her/their consent for his/her/their images and other clinical information to be reported in the journal. The patients understand that their names and initials will not be published and due efforts will be made to conceal their identity, but anonymity cannot be guaranteed.

Acknowledgment

We would like to thank Dr. Sonali Deshmukh, MD. Department of Radiology, Deenanath Mangeshkar Hospital, Pune, Maharashtra, India. Dr. Sheetal Biradar, MD. Department of Pathology, Deenanath Mangeshkar Hospital, Pune, Maharashtra, India Novo Life Cancer Clinic, Pune, Maharashtra, India.

Financial support and sponsorship

Nil.

Conflicts of interest

There are no conflicts of interest.

Anup Sunil Tamhankar, Tanuja Anup Tamhankar¹

Department of Surgical Oncology, Deenanath Mangeshkar Hospital,
¹Department of Surgical Oncology, Novo Life Cancer Clinic, Pune,
Maharashtra, India

Correspondence to: Dr. Anup Sunil Tamhankar,
E-mail: tamhankaranup@gmail.com

References

1. Burkill GJ, Badran M, Al-Muderis O, Meirion Thomas J, Judson IR, Fisher C, *et al.* Malignant gastrointestinal stromal tumor: Distribution, imaging features, and pattern of metastatic spread. *Radiology* 2003;226:527-32.
2. Miettinen M, Lasota J. Gastrointestinal stromal tumors – Definition, clinical, histological, immunohistochemical, and molecular genetic features and differential diagnosis. *Virchows Arch* 2001;438:1-2.
3. Hansen Cde A, José FF, Caluz NP. Gastrointestinal stromal tumor (GIST) mistaken for pancreatic pseudocyst – Case report and literature review. *Clin Case Rep* 2014;2:197-200.
4. Hamza AM, Ayyash EH, Alzafiri R, Francis I, Asfar S. Gastrointestinal stromal tumour masquerading as a cyst in the lesser sac. *BMJ Case Rep* 2016;2016:pil: bcr2016215479. [doi: 10.1136/bcr-2016-215479].
5. Zhu CC, Liu Y, Zhao G. Exophytic gastrointestinal stromal tumor with cystic changes: A case report. *Oncol Lett* 2014;7:1427-9.

This is an open access article distributed under the terms of the Creative Commons Attribution-NonCommercial-ShareAlike 3.0 License, which allows others to remix, tweak, and build upon the work non-commercially, as long as the author is credited and the new creations are licensed under the identical terms.

How to cite this article: Tamhankar AS, Tamhankar TA. A large cystic gastrointestinal stromal tumor within lesser sac: A diagnostic dilemma. *South Asian J Cancer* 2018;7:4-10.

© 2018 The South Asian Journal of Cancer | Published by Wolters Kluwer - Medknow