

## Letter to the Editor

### Osimertinib in Indian patients with T790M-positive advanced nonsmall cell lung cancer

DOI: 10.4103/sajc.sajc\_202\_17

Dear Editor,

The recent AURA3 trial<sup>[1]</sup> has renewed hopes in the management of T790M mutation-positive advanced lung cancer. Osimertinib, an irreversible, oral tyrosine kinase inhibitor (TKI) directed at both epidermal growth factor receptor (EGFR) and T790M mutation, used in advanced T790M mutation-positive nonsmall cell lung cancer (NSCLC) showed median progression-free survival of 10.1 months compared with 4.4 months in patients treated with platinum-pemetrexed. Given this background, we report our first experience of osimertinib in 13 patients of T790M mutation-positive advanced NSCLC.

We administered Osimertinib 80 mg once daily in 13 T790M-positive patients in the relapsed setting. Complete hemogram, liver and renal function tests, urine routine, and ECG for QTc prolongation were monitored. Majority of the patients were women (8) and nonsmokers (11). The types of EGFR mutation at the time of diagnosis included in-frame deletion in exon 19 (6, 46%), L858R point mutation in exon 21 (6, 46%) and 1 (8%) upfront T790M mutation. 12 patients had received oral TKI (gefitinib/erlotinib) for a median duration of 11.2 months (range: 4.6–20.8 months) before osimertinib. Ten out of 13 patients had received  $\geq 2$  lines of therapy.

Median duration of follow-up was 2.5 months (range 1.4–5.7 months). 9 of 12 patients experienced a reduction in symptoms after starting therapy with osimertinib

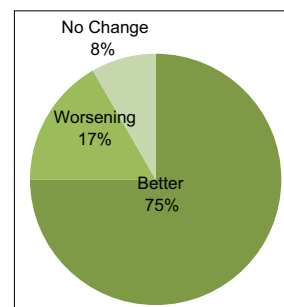
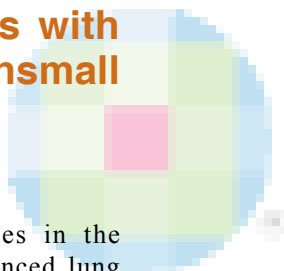


Figure 1: Clinical response (n=12)

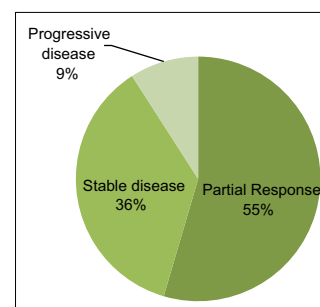


Figure 2: Radiological response (n=11)

[Figure 1]. Eleven out of 13 patients had radiological response evaluation. By revised RECIST 1.1 criteria, 6/11 (55%) had partial response, 4/11 (37%) had stable disease, and 1 had progressive disease as the best response [Figure 2]. Reason for treatment discontinuation in two patients was clinical progression in one and the Grade 3 toxicity in the other. Nine of the 13 (70%) reported no treatment-related toxicity. Grade I/II rash was seen in three patients. Two patients had Grade I/II thrombocytopenia. One patient after 2.2 months of therapy developed Grade 3

(Continue on page 146...)

(Letter to the editor continue from page 143...)

esophagitis and hyponatremia requiring discontinuation of osimertinib. He was again started on osimertinib after interruption but did not tolerate osimertinib even as an alternate day dosing.

In the AURA3 study<sup>[1]</sup> in which osimertinib was compared to pemetrexed-platinum therapy in patients with T790M positive advanced NSCLC after first-line oral TKI therapy, the objective response rate to osimertinib was 71% (95%CI, 65 to 76) compared to 31% (95%CI, 24 to 40) in the pemetrexed-platinum arm. In our very early experience with the use of osimertinib, we report a relatively similar response rate and a toxicity profile that was mild and acceptable. Follow-up is short and hence data on survival endpoints are immature.

#### Financial support and sponsorship

Nil.

#### Conflicts of interest

There are no conflicts of interest.

**Vanita Noronha, Swaratika Majumdar, Amit Joshi,  
Vijay Patil, Vaishakhi Trivedi, Anuradha Chougule,  
Kumar Prabhash**

Department of Medical Oncology, Tata Memorial Hospital, Mumbai,  
Maharashtra, India

**Correspondence to:** Dr. Kumar Prabhash,  
E-mail: [kumarprabhashtmh@gmail.com](mailto:kumarprabhashtmh@gmail.com)

#### Reference

1. Mok TS, Wu YL, Ahn MJ, Garassino MC, Kim HR, Ramalingam SS, *et al*. Osimertinib or platinum-pemetrexed in EGFR T790M-positive lung cancer. *N Engl J Med* 2017;376:629-40.

This is an open access article distributed under the terms of the Creative Commons Attribution-NonCommercial-ShareAlike 3.0 License, which allows others to remix, tweak, and build upon the work non-commercially, as long as the author is credited and the new creations are licensed under the identical terms.

**How to cite this article:** Noronha V, Majumdar S, Joshi A, Patil V, Trivedi V, Chougule A, *et al*. Osimertinib in Indian patients with T790M-positive advanced nonsmall cell lung cancer. *South Asian J Cancer* 2017;6: 143-6.

© 2017 The South Asian Journal of Cancer | Published by Wolters Kluwer - Medknow