

# Role of neoadjuvant chemotherapy in advanced carcinoma of the hypopharynx and larynx

Poonam Joshi, Amit Joshi, Vanita Norohna, Pankaj Chaturvedi, Vijay Patil, Jai Prakash Agarwal, Shashikant Juvekar, Kumar Prabhash

## Abstract

**Background:** To assess the response rate and impact of neoadjuvant chemotherapy (NACT) in advanced carcinoma of the hypopharynx and larynx. **Materials and Methods:** This is a retrospective case series of 80 patients with locally advanced laryngopharynx carcinoma who received NACT from April 2010 to October 2011 at our tertiary care center. The patients received NACT either for achieving resectability or for organ preservation. **Results:** Majority of the patients (60%) had T4 a disease. Grade 3 and 4 neutropenia was seen in 18%, febrile neutropenia in 4%, mucositis in 4%, diarrhea in 5%, and vomiting in 3% patients. Resectability could be achieved in 34%, and larynx was preserved in 51% patients at a mean follow-up of 13 months. **Conclusions:** NACT was safe with acceptable toxicity. Majority of the patients who achieved resectability had oropharyngeal involvement. NACT followed by concurrent chemoradiotherapy could provide a high rate of organ preservation.

**Key words:** Advanced carcinoma, hypopharynx, larynx, neoadjuvant chemotherapy

## Introduction

Concurrent chemoradiotherapy is the treatment of choice for locally advanced laryngeal-hypopharyngeal cancers for organ preservation.<sup>[1-4]</sup> Surgery remains the choice of treatment in locally advanced laryngeal-hypopharyngeal malignancies when organ preservation is not feasible. However, treatment guidelines fail to define borderline resectable T4 lesions which may not be amenable for surgical excision. These include advanced laryngeal or hypopharyngeal tumors with either of the below mention criteria:

1. Exolaryngeal spread either via the laryngeal membranes without cartilage erosion or through cricothyroid space
2. Extension to oropharynx or with the involvement of prevertebral fascia or parapharyngeal space.

Surgery in such situations often leads to positive margins and the morbidity of extensive surgery is unacceptably high. In cases of bulky N3 nodes treated with concurrent chemoradiotherapy, response rates are poor.<sup>[5]</sup> Neoadjuvant chemotherapy (NACT) is also one of the modality of treatment recommended by NCCN for advanced laryngeal-hypopharyngeal cancers. The hypothesis of the present study is that NACT may be useful in selecting patients for appropriate definitive treatment depending upon the response to chemotherapy.

## Materials and Methods

This is a retrospective analysis of 80 patients with locally advanced carcinoma of the hypopharynx and larynx, who received NACT from April 2010 to October 2011 at our tertiary care center. The medical details of these patients were retrieved from medical records of the hospital. Cases were selected based on the following eligibility criteria: (1) Biopsy confirmed squamous cell carcinoma of the hypopharynx and larynx (2) all these patients were treatment Naïve at presentation, (3) patients with bulky T3 disease or with inner cartilage erosion/T4 disease with extensive soft tissue involvement, and (4) patients with N3 nodes or nodes with restricted mobility or skin involvement.

Of the total 99 patients who were treated, 80 patients were eligible for analysis as complete clinical data was available in these 80 patients. Twelve patients started chemotherapy at our hospital but did not complete treatment due to logistic reasons and took treatment at their local place, details of which are not available. Rest 7 patients, did not come for a single follow-up postdefinitive treatment, and no further details about them were available. Hence, they were excluded from the study.

A complete medical history of the patients was obtained. Complete preoperative evaluation was done in all patients including a direct laryngoscopy, imaging with contrast enhanced computed tomography (CT) scans, magnetic resonance imaging, or positron emission tomography scans whenever indicated.

NACT was given either as two-drug (platinum + taxane) or three-drug combination (platinum + taxane + 5 fluorouracil [5FU]). These patients were not suitable for definitive treatment at presentation due to advanced disease.

These patients were divided into two groups depending upon the intent of giving NACT: (a) Group 1 (35/80) - The intent of giving NACT was to achieve resectability. Patients with extensive soft tissue/skin involvement, Oro-pharyngeal involvement, cartilage erosion with extensive soft tissue disease were included. These patients had gross cartilage erosion, exolaryngeal disease and nonfunctional larynx (tracheostomized). Hence, these patients were considered for surgery. Patients with T4 disease and nonfunctional larynx undergo standard surgery at our center. (b) Group 2 (45/80) - The intent of giving NACT was to achieve Organ preservation. Patients with bulky disease, inner cartilage erosion, exolaryngeal disease without cartilage erosion, N3 nodes or nodes with restricted mobility/skin involvement were included.

The primary objectives of the study were resectability and organ preservation.

Secondary objectives were response rate of tumor to NACT, side effects, progression-free survival, overall survival. Resectability was defined as tumors in which adequate margins

This is an open access article distributed under the terms of the Creative Commons Attribution-NonCommercial-ShareAlike 3.0 License, which allows others to remix, tweak, and build upon the work non-commercially, as long as the author is credited and the new creations are licensed under the identical terms.

**For reprints contact:** [reprints@medknow.com](mailto:reprints@medknow.com)

**How to cite this article:** Joshi P, Joshi A, Norohna V, Chaturvedi P, Patil V, Agarwal JP, *et al.* Role of neoadjuvant chemotherapy in advanced carcinoma of the hypopharynx and larynx. *South Asian J Cancer* 2017;6:15-9.

Access this article online

Quick Response Code:



Website: [www.sajc.org](http://www.sajc.org)

DOI: 10.4103/2278-330X.202557

Department of Medical Oncology, Tata memorial Hospital, Mumbai, Maharashtra, India

**Correspondence to:** Dr. Kumar Prabhash,  
E-mail: [kprabhash1@gmail.com](mailto:kprabhash1@gmail.com)

could be achieved post-NACT. Organ preservation was defined as the treatment with chemoradiotherapy with preservation of larynx.

NACT was given as two or three drug as 3 weekly regimen with cisplatin and docetaxel as 75 mg/m<sup>2</sup> each on day 1 and 5-fluorouracil as 750 mg/m<sup>2</sup> as 24 h intravenous (IV) infusion for 5 days for three cycles. Patients receiving three-drug regimens were given granulocyte-colony stimulating factor prophylactically from day 6 to 12. Tablet levofloxacin 500 mg once daily was given for same duration as a primary prophylaxis for bacterial infections. Carboplatin as AUC 6 was given to older individuals or those with compromised glomerulo-filtration rate of <60 ml/min.

All patients received standard prophylactic 5-HT<sub>3</sub> antagonists (ondansetron/granisetron). Patients receiving cisplatin, in addition, received neurokinin 1 receptor antagonist aprepitant for delayed emesis. All patients received premedication for taxanes in the form of H<sub>2</sub> blockers (ranitidine), antihistaminics (phenargan), and dexamethasone. Patients who completed two cycles of NACT were included in the study.

In majority of patients, two drugs were used due to logistic reasons and economic constraints. Poor performance status and low creatinine clearance were other reasons. Cisplatin/carboplatin + docetaxel/paclitaxel were used in two drug regimen, and 5FU was used in addition in three-drug regimen.

Clinical response and toxicities were assessed on day 8 and 20 of the cycle. Post 2 cycles of NACT, patients were assessed for further management in multidisciplinary joint clinic. Response assessment was done with RECIST criteria 1.1. All CT scans were evaluated by a senior radiologist pre- and post-NACT. Side effects were assessed with common toxicity criteria version 4. Dose reduction was done for Grade 3 or 4 toxicities. Patients with sufficient tumor shrinkage underwent surgery in the first group. In the other group, where the intent was organ preservation, patients were considered for concurrent chemoradiotherapy/radiotherapy.

Those patients who had progressive disease (PD) were treated with palliative radiotherapy/chemotherapy or best supportive care. All patients were followed up till progression, recurrence or death whichever occurred first. Censoring of data was done on March 2013, and data were analyzed after updating the records through electronic medical records.

Tumor responses were assessed by clinical evaluation and imaging studies done 12 weeks after the completion of chemoradiotherapy. Patients were monitored every 3 monthly for recurrence for first 2 years by clinical examination or imaging if required. In our study, the follow-up varied from 2 months to 27 months.

Statistical analysis was done using the software SPSS 20.0 (IBM, NY, USA).

Calculation of values was done in percentages. Survival was calculated with Kaplan–Meier analysis [Figures 1-4].

## Results

The mean age of the population was 54 years (range - 22–80 years). Pyriform sinus was involved in 61% and supraglottic larynx in 19% patients. Sixty percent of the tumors

were T4a, and 6% were T4b. The tumor, nodal status and stage of the disease and Eastern Cooperative Oncology Group scale are described in Table 1. The median hemoglobin of the population was 12.35 g/dl (8.9–17.2 g/dl), and median albumin was 4 mg/dl (2.7–4.7 mg/dl).

Patients were given NACT due to various reasons as shown in Table 2. Sixty-seven patients received two cycles of chemotherapy, and 13 patients received three cycles. Sixty patients received two drug regimen and 20 received three-drug regimen. Either docetaxel or paclitaxel was used [Table 3].

Response to NACT and suitability for resectability or organ preservation were assessed at the completion of two cycles of NACT in the two groups. The overall response rate (complete response [CR] + partial response [PR]) was 58% with 5% CR and 53% PR rate. Thirty-seven patients had stable disease, and 5% had PD. The response assessment when done separately for primary and nodes was 71% and 59%, respectively.

The Grade 3 and 4 toxicities of NACT were neutropenia in 18%, febrile neutropenia in 4%, mucositis in 4%, diarrhea

**Table 1: Demographic details (n=80)**

Age Variables	Age in years	
Age (years)		
Mean	54	
Median	54	
Range	22-80	
	Number of patients	Percentage
Sex		
Male	72	90
Female	08	10
Site of the disease		
Pyriform sinus	49	61
Postcricoid	07	09
Posterior pharyngeal wall	03	04
Supraglottis	15	19
Glottis	05	06
Subglottis	01	01
Tumor status		
T1	01	01
T2	04	05
T3	22	28
T4a	48	60
T4b	05	06
Nodal status		
N0	23	29
N1	10	13
N2a	10	12
N2b	15	19
N2c	09	11
N3	13	16
Staging		
Stage III	06	07
Stage IVa	56	70
Stage IVb	18	23
ECOG performance status		
0	06	07
1	68	86
2	06	07
3	0	0
4	0	0

ECOG=European Cooperative Oncology Group

in 5%, and thrombocytopenia in 1% patients. Other side effects included nausea, anorexia, hiccough, renal dysfunction, hypokalemia, and hyponatremia. The toxicities are elaborately described in Table 4.

Post-NACT, 12 patients (12/35) underwent radical treatment in the form of total laryngectomy or total laryngectomy with partial/total pharyngectomy in the first group. All patients had R0 resection. The margins were wide in 10 patients, close in 2 patients. Four patients achieved complete pathological response with NACT.

All 12 patients received adjuvant postoperative chemoradiation or radiotherapy. Weekly cisplatin at a dose of 30 mg/m<sup>2</sup> was given as an IV infusion for 1 h period for 6–7 weekly doses during the course of radiotherapy. The definitive curative radiation dose administered to the primary tumor was between 66 and 70 Gy, administered as fractions of 2 Gy/day 5 days/week.

Four patients received palliative radiotherapy and 1 patient symptomatic care in view of progressive, unresectable disease. Remaining 18 patients were discussed in joint clinic and were given chemoradiotherapy or radiotherapy with mean dose of 60–70 Gy.

Following NACT, resectability was achieved in (12/35) 34% patients. The reasons for achieving resectability were shrinkage in tumor size, disappearance of diffuse edema/inflammation of the overlying skin or soft tissues thus enabling resection with free margins. Majority of these patients had disease extending to oropharynx (50%, 6/12). Two patients developed nonsalvageable recurrences, one locally and the other regionally with distant metastasis. Eighty-three percent (10/12) patients in this group were disease free at a mean follow-up of 12 months.

In the other group, where the intent was organ preservation,

29 patients received radical chemoradiotherapy and 10 patients received radical radiotherapy. One patient received only 40 Gy dose of radiotherapy as he developed trachea-esophageal fistula. One received palliative radiation therapy due to the progression of nodal disease, and encasement of carotid artery and one patient was considered for symptomatic care due to the progression and fungation of nodal disease. One patient died due to septicemia following febrile neutropenia post-NACT. Two patients denied further treatment although, both had achieved PR.

Salvage total laryngectomy was done for one patient who had resectable residual disease at the primary site and neck dissection in 1 patient, postradiotherapy.

The larynx preservation rate was calculated for those patients only where the initial intent was organ preservation. Hence, larynxes were preserved in 51% (23/45) patients and were disease-free after a mean follow-up of 13 months.

The pattern of failure was mostly regional followed by local recurrence. The patterns of failure, shown in Table 5, show the site of first failures. Four patients who did not receive definitive treatment post-NACT were excluded from this analysis.

The median progression-free survival (PFS) in the first group where the intent of NACT was resectability was 20 months and in those where the intent was organ preservation was 19 months respectively. The mean overall survival was 22 months, and median was not reached in both the groups.

### Discussion

In view of the advanced stage at the time of presentation, hypopharyngeal cancers carry a poor prognosis.<sup>[6-10]</sup> NACT has been used advanced head and neck cancers with the aim of organ preservation and for the achievement of resectability.<sup>[11,12]</sup> Majority of international trials have used three-drug TPF regimen for induction.<sup>[13-15]</sup> However, we have used a two-drug regimen of taxane and platinum in majority patients. The two drug regimen was found to be cheaper, easy to administer, less toxic, and has reasonably good response. The response to NACT was in accordance with the RECIST criteria 1.1. We observed that taxanes have similar efficacy but lesser toxicity as compared to conventional regimens of platin with FU.<sup>[16]</sup> In our series, the overall response rate was 58%, including 5% CR and 53% PR rate. TAX 324 reported 72% and 64% response rates with TPF and PF, respectively.<sup>[17]</sup> Toxicities were much less in our series with Grade 3 or 4 neutropenia in 18% and thrombocytopenia in 1% patients, whereas in TAX 324 trial, the Grade 3 or 4 neutropenia was 83% in TPF and 56% in PF. The Grade 3 or 4 thrombocytopenia was 11% and 4%, respectively. This could be attributed to use of two drugs and two cycles of NACT in majority of the patients in our study.

Although all patients had advanced stage disease, the two groups were different. The first group had cartilage erosion,

**Table 2: Various reasons for giving neoadjuvant chemotherapy (%)**

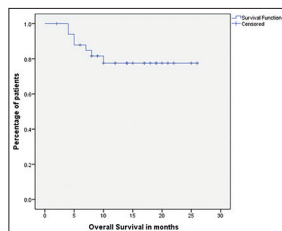
Reasons for NACT	Number of patients	Percentage of patients
Oropharyngeal involvement	21	26
N3 node/restricted mobility	13	16
Extensive exolaryngeal disease with cartilage erosion	11	14
Exolaryngeal disease without cartilage erosion	05	06
Extensive disease with doubtful thyroid cartilage invasion	10	13
Bulky/extensive disease	12	15
Prevertebral muscle involvement/abutment	03	04
Parapharyngeal/retropharyngeal spaces involvement	02	02
Carotid artery encasement	03	04

NACT=Neoadjuvant chemotherapy

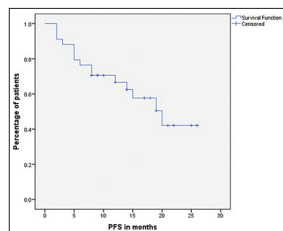
**Table 3: Chemotherapy drug regimen and number of cycles given**

Number of cycles given	Cisplatin + docetaxel	Cisplatin + paclitaxel	Carboplatin + docetaxel	Carboplatin + paclitaxel	Three-drug regimen docetaxel + cisplatin + 5FU	Total
2 cycles	13	17	12	10	15	67
3 cycles	3	2	3	0	5	13
Total	60				20	80

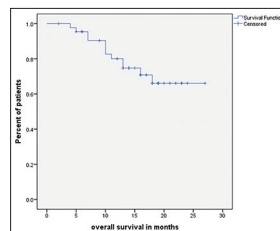
5FU=5-fluorouracil



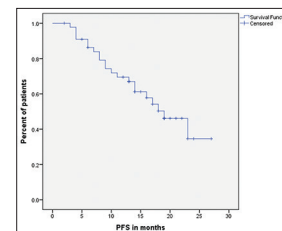
**Figure 1: Kaplan–Meier curve showing overall survival in patients where the intent of neoadjuvant chemotherapy was resectability**



**Figure 2: Kaplan–Meier curve showing progression-free survival in patients where the intent of neoadjuvant chemotherapy was resectability**



**Figure 3: Kaplan–Meier curve showing overall survival in patients where the intent of neoadjuvant chemotherapy was organ preservation**



**Figure 4: Kaplan–Meier curve showing progression-free survival in patients where the intent of neoadjuvant chemotherapy was organ preservation**

**Table 4: Toxicities of neoadjuvant chemotherapy**

	Grade 1	Grade 2	Grade 3	Grade 4	None
Vomiting	18	48	03	0	31
Mucositis	19	33	02	04	42
Diarrhea	17	31	03	02	47
Neutropenia	06	15	24	21	34
Febrile neutropenia			02	02	96
Thrombocytopenia	06	05	01	0	88
Peripheral neuropathy	03	02	0	0	95
Hiccoughs	01	01	0	0	98
Renal dysfunction	05	03	03	0	89
Anorexia	08	12	3	0	77
Nausea	02	04	01	0	93
Hypokalemia	18	03	14	03	62
Hyponatremia	25		28	05	42
Anemia	13	27	07	01	52

**Table 5: Pattern of recurrence**

Site of recurrence	Number	Percentage
Local	6	26
Regional	7	31
Local + regional	3	13
Distant metastasis	1	4
Local + regional + distant metastasis	3	13
Regional + distant	3	13
Total	23	100

extensive skin and soft tissue involvement that was not amenable to surgery. While the other group had bulky laryngopharynx disease, high volume nodal disease, and conventional concurrent chemoradiotherapy were considered inadequate.

In these selected groups of advanced larynx and hypopharynx cancer patients, NACT is being increasingly offered in our institution since last 3–4 years. Surgery is still the standard of care for T4 operable larynx and hypopharynx cancers and organ preservation with chemoradiotherapy for T3 cancers. NACT is given only in above described situations where the disease is very advanced and extensive and not suitable for surgery or organ preservation. With the use of NACT, a reasonably good number of patients achieved resectability and organ preservation in their respective groups. A high PR translated into definitive treatment in these advanced larynx and hypopharynx cancers.

The limitation of present study is that it was a retrospective study, patient groups involved were heterogenous and the drugs/regimens were not homogenous. It had a short follow-up period to conclude about disease-free and overall survival. Toxicity data shows less toxicity due to the use of two-drug

regimen in majority of the patients and retrospective nature of the study. As data are sparse in literature about the management of moderately and very advanced laryngopharyngeal cancers, this data will be a good guide for the clinicians in making decisions.

### Conclusion

NACT is a safe and feasible method with acceptable toxicity. It can be used to achieve resectability in advanced cancers of the larynx and hypopharynx with oropharyngeal involvement. NACT followed by concurrent chemoradiotherapy could provide a high rate of organ preservation in advanced cancers of larynx and hypopharynx.

### Financial support and sponsorship

Nil.

### Conflicts of interest

There are no conflicts of interest.

### References

1. Wolf GT, Hong WK, Fisher SG, Urba S, Endicott JW, Close L, *et al.* Induction chemotherapy plus radiation compared with surgery plus radiation in patients with advanced laryngeal cancer. The Department of Veterans Affairs Laryngeal Cancer Study Group. *N Engl J Med* 1991;324:1685-90.
2. Forastiere AA, Goepfert H, Maor M, Pajak TF, Weber R, Morrison W, *et al.* Concurrent chemotherapy and radiotherapy for organ preservation in advanced laryngeal cancer. *N Engl J Med* 2003;349:2091-8.
3. Corvò R. Evidence-based radiation oncology in head and neck squamous cell carcinoma. *Radiother Oncol* 2007;85:156-70.
4. Hall SF, Groome PA, Irish J, O’Sullivan B. Radiotherapy or surgery for head and neck squamous cell cancer: Establishing the baseline for hypopharyngeal carcinoma? *Cancer* 2009;115:5711-22.
5. Hanna E, Alexiou M, Morgan J, Badley J, Maddox AM, Penagaricano J, *et al.* Intensive chemoradiotherapy as a primary treatment for organ preservation in patients with advanced cancer of the head and neck: Efficacy, toxic effects, and limitations. *Arch Otolaryngol Head Neck Surg* 2004;130:861-7.
6. Horwitz SD, Caldarelli DD, Hendrickson FR. Treatment of carcinoma of the hypopharynx. *Head Neck Surg* 1979;2:107-11.
7. Uzcudun AE, Bravo Fernández P, Sánchez JJ, García Grande A, Rabanal Retolaza I, González Barón M, *et al.* Clinical features of pharyngeal cancer: A retrospective study of 258 consecutive patients. *J Laryngol Otol* 2001;115:112-8.
8. Keane TJ. Carcinoma of the hypopharynx. *J Otolaryngol* 1982;11:227-31.
9. Spector JG, Sessions DG, Haughey BH, Chao KS, Simpson J, El Mofty S, *et al.* Delayed regional metastases, distant metastases, and second primary malignancies in squamous cell carcinomas of the larynx and hypopharynx. *Laryngoscope* 2001;111:1079-87.
10. Howlader N, Noone AM, Krapcho M, Garshell J, Neyman N, Altekruse SF, *et al.* SEER Cancer Statistics Review, 1975–2010. Bethesda, MD: National Cancer Institute; 2012. Available from: [http://www.seer.cancer.gov/csr/1975\\_2010](http://www.seer.cancer.gov/csr/1975_2010). [Last accessed on 2015 Apr].
11. Bernier J, Bentzen SM. Altered fractionation and combined radio-chemotherapy approaches: Pioneering new opportunities in head and neck oncology. *Eur J Cancer* 2003;39:560-71.
12. Specenier PM, Vermorken JB. Neoadjuvant chemotherapy in head and neck cancer: Should it be revisited? *Cancer Lett* 2007;256:166-77.

13. Lefebvre JL, Andry G, Chevalier D, Luboinski B, Collette L, Traissac L, *et al.* Laryngeal preservation with induction chemotherapy for hypopharyngeal squamous cell carcinoma: 10-year results of EORTC trial 24891. *Ann Oncol* 2012;23:2708-14.
14. Lefebvre JL, Rolland F, Tessler M, Bardet E, Leemans CR, Geoffrois L, *et al.* Phase 3 randomized trial on larynx preservation comparing sequential vs alternating chemotherapy and radiotherapy. *J Natl Cancer Inst* 2009;101:142-52.
15. Pointreau Y, Garaud P, Chapet S, Sire C, Tuchais C, Tortochaux J, *et al.* Randomized trial of induction chemotherapy with cisplatin and 5-fluorouracil with or without docetaxel for larynx preservation. *J Natl Cancer Inst* 2009;101:498-506.
16. Gibson MK, Li Y, Murphy B, Hussain MH, DeConti RC, Ensley J, *et al.* Randomized phase III evaluation of cisplatin plus fluorouracil versus cisplatin plus paclitaxel in advanced head and neck cancer (E1395): An intergroup trial of the Eastern Cooperative Oncology Group. *J Clin Oncol* 2005;23:3562-7.
17. Posner MR, Hershock DM, Blajman CR, Mickiewicz E, Winquist E, Gorbounova V, *et al.* Cisplatin and fluorouracil alone or with docetaxel in head and neck cancer. *N Engl J Med* 2007;357:1705-15.